


## Piezoelectric Surgery in Implantology: A Case Report—A New Piezoelectric Ridge Expansion Technique



Tomaso Vercellotti, MD, DDS\*

*The purpose of this preliminary article is to present a new surgical technique that, thanks to the use of modulated-frequency piezoelectric energy scalpels, permits the expansion of the ridge and the placement of implants in single-stage surgery in positions that were not previously possible with any other method. The technique involves the separation of the vestibular osseous flap from the palatal flap and the immediate positioning of the implant between the 2 cortical walls. The case report illustrates the ridge expansion and positioning of implants step by step in bone of quality 1 to 2 with only 2 to 3 mm of thickness that is maintained for its entire height. To obtain rapid healing, the expansion space that was created for the positioning of the implant was filled, following the concepts of tissue engineering, with bioactive glass synthetic bone graft material as an osteoconductive factor and autogenous platelet-rich plasma as an osteoinductive factor. The site was covered with a platelet-rich plasma membrane. A careful evaluation of the site when reopened after 3 months revealed that the ridge was mineralized and stabilized at a thickness of 5 mm and the implants were osseointegrated. (Int J Periodontics Restorative Dent 2000;20:359–365.)*

\*Private Practice, Genova and Merano, Italy.

Reprint requests: Dr Tomaso Vercellotti, Via XII Ottobre 2/111, 16121 Genova, Italy.

The presence of a thin edentulous ridge in the maxilla represents a clinical situation in which the positioning of endosseous implants can be complex, and at times impossible, in a single surgical operation. In fact, the minimum thickness of the implant site for the standard method, that is, with preparation of the implant site using burs, is at least 6 mm to permit the positioning of a 3.75-mm implant and the maintenance of a buccal and palatal wall of at least 1 mm.<sup>1–4</sup>

When the thickness of the ridge is reduced to about 4 mm in the most coronal position and the volume increases in the apical direction, preparation of the implant site with burs produces a dehiscence that is generally vestibular and leads to the exposure of several millimeters of the thread of the implant. This dehiscence has to be considered a defect to be treated with additional therapy,<sup>5–8</sup> such as bone grafting and/or guided bone regeneration. This factor reduces the predictability of the treatment because of eventual membrane collapse, exposure, and infection, with incomplete reformation of the bone.<sup>9</sup> When atrophy is

even more severe and the ridge is less than 4 mm and it does not present an apical expansion, the standard method with burs must be abandoned because its use will bring about the complete destruction of the residual crestal bone.

As sufficient bone volume is the fundamental prerequisite for osseointegration, some authors<sup>10-13</sup> maintain that the positioning of the implant must be preceded by a bone graft that, once established and mineralized, offers sufficient volume for the standard method. These bone-grafting methods, which are not without risk of complications during the healing period, necessitate 2 surgical operations. This doubles the time necessary to finalize the implants.

Some authors<sup>14-17</sup> prefer to use ridge expansion techniques with immediate positioning of the implants to avoid unwanted dehiscence or fenestration that necessitates additional therapy. Osteotomy, as described by Summers,<sup>14-16</sup> produces immediate expansion of the single implant site by the insertion of osteotomes of increasing dimension and permits positioning of the implant in thin ridges of 3 to 4 mm in thickness. This is a less traumatic method that does not remove bone from the implant site but dislocates it, increasing the volume without provoking any defect that will necessitate additional therapy. Even the bone flap technique<sup>17</sup> permits positioning of the implants at the same time as the expansion, which consists of distancing the vestibular crestal wall from the palatal wall with the formation of an ample defect with

morphologic characteristics that are extremely favorable to bone healing. In fact, the tissue repair is protected from microtraumas by the presence of the vestibular and palatal cortical walls and is comparable to a fracture rima characterized by a valid vascular supply and a rich osteoinductive cellularity, which comes from the diversion of the medulla.

Both of these expansion techniques make use of the elasticity of the bone ridge and are recommended in the presence of tender quality bone (Types 3 to 4), but they have mechanical limits when the residual bone is extremely mineralized because the mechanical expansion maneuvers can produce uncontrolled fractures. When inelastic cortical walls are separated, the eventual fracture of one of the walls produces the total detachment of the vestibular cortical bone and the consequent interruption of the vascularization process, provoking bone death and the loss of the implants.

It is the author's opinion that the traditional mechanical expansion methods cannot be used with predictable outcome in the presence of a very mineralized bone ridge as is often seen in a long-standing edentulous zone. The basis of the new piezoelectric ridge expansion technique is the use of variable-frequency piezoelectric energy as a powerful and efficacious surgical force that is able to cut bone without uncontrollable traumas. This permits the expansion of the edentulous ridge no matter what the quality of the bone, even in the case of the most mineralized.

This new method, which is presented here as a case report, permits the surgeon to obtain the expansion of a very mineralized bone ridge (quality 1) of 2 to 3 mm in thickness at the same time as the positioning of the implants, intervening where it has been impossible with other techniques. The fundamental idea on which piezoelectric surgery is based is the use of a surgical force that is able to cut bone according to the requirements of the case, with a powerful and precise energy and without excessive traumas or the risk of fracturing the ridge.

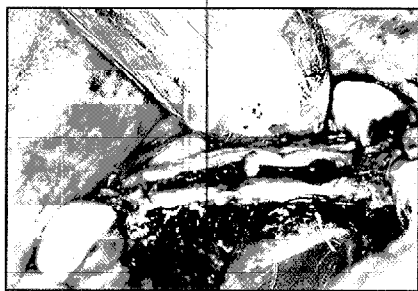## Method and materials

The patient was a man of 55 years of age. His medical history indicated arterial hypertension that was under medical treatment. His dental history included precocious loss of the left lateral incisor, canine, first and second premolars, and molar about 20 years previously. During the clinical examination, a ridge defect with reduction in the thickness of the bone, which appeared to be thin, was diagnosed. A computed tomographic (CT) scan demonstrated adequate ridge height, and the paraxial lines of the implant sites showed a thickness of less than 3 mm for the entire development of the apical crown. The bone quality was Type 1 to 2, and the cancellous residue only appeared as a line of minor radiolucency separating the vestibular cortical bone from the palatal bone (Fig 1).

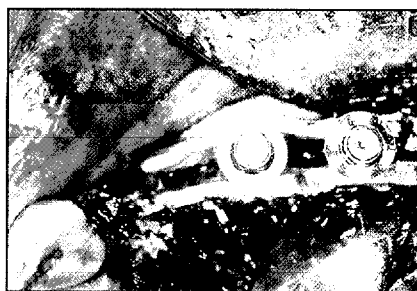for 5 days was prescribed. The post-operative pain was controlled with 100 mg of nimesulide (Aulin, Helsinn

teeth, and rinse with a saline solution twice a day for another 2 weeks.

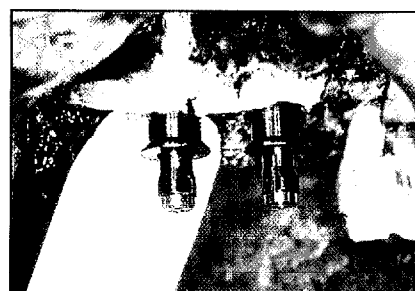
were extended into the vestibule. A mucoperiosteal flap of the total thickness of the summit of the bone




**Fig 7** Implant sites have been created with a 2-mm twist drill following the use of piezoelectric osteotome V3.



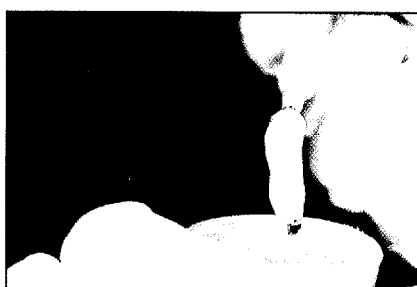**Fig 8** View of the expanded ridge after the positioning of the implants.



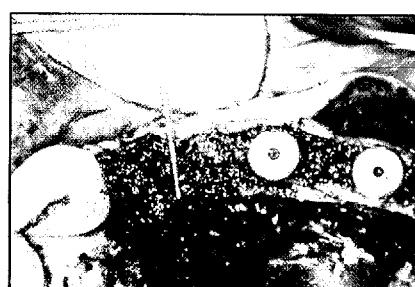
**Fig 9** Lateral view after positioning of the implants: the integrity of the vestibular cortical wall without dehiscence or fenestration can be observed.



**Fig 10** View of the ridge with the implants, which maintain their separate bone flaps. Piezoelectric scalpel M1 creates microopenings on the vestibular and palatal walls to stimulate bleeding on the inside of the surgical wound.



**Fig 11** Gel formed of bioactive glass synthetic bone graft material and autogenous PRP obtained from a 50-mL venous blood sample 30 minutes before the surgery.



**Fig 12** Implants are in position and the surgical wound is filled with the bone graft material and PRP.

ridge was lifted and then continued with a flap of partial thickness in the vestibular fornix. This flap permitted the denuding of the summit of the ridge while maintaining the periosteum on the vertical walls and permitting the creation of an extremely mobile mucous flap that permitted suturing without any tension after the expansion. Using a periodontal probe, various measurements were made of the ridge, which had a thickness of from 2.2 to 2.8 mm (to be verified after projecting the image)

(Fig 2). The top of the ridge was leveled with a diamond bur to obtain a uniform surface of 2.5 mm in thickness (Fig 3). A horizontal incision was then made in the middle of the ridge with the first piezoelectric scalpel, V1 (Mectron Piezo Surgery Device), and 2 releasing incisions were made to a depth of 5 mm in the vestibular bone (Figs 4 and 5). Another 2 scalpels of greater length and thickness were successively inserted apically to obtain a mobile vestibular flap (Fig 6).

The implant site was prepared with a 2-mm twist drill and a piezoelectric osteotome of 3 mm, above all on the palatal side (Fig 7), to obtain an apical implant alveolus that guaranteed the primary stability of the 2 implants; this would ensure that, once inserted, the implants would not undergo dehiscence or fenestration, but maintain their separate bone surfaces (Figs 8 and 9). Microopenings were oppositely created in the vestibular and palatal bone flap with an M1 insert to




Fig 13 Ridge is covered with a PRP membrane to protect and stabilize the graft.



Fig 14 Flaps are sutured on 2 sides with horizontal mattress stitches on the periosteum; normal stitches are used on the upper surface.




Fig 15 View of the ridge after 3 months, at reopening; it is possible to see the heads of the implants through the palatal mucosa. The implants are in a vestibular position without keratinized tissue.

Fig 16 (left) View after reopening, with healing abutments in place. The palatal flap has been positioned vestibularly to obtain 3 mm of attached gingiva.

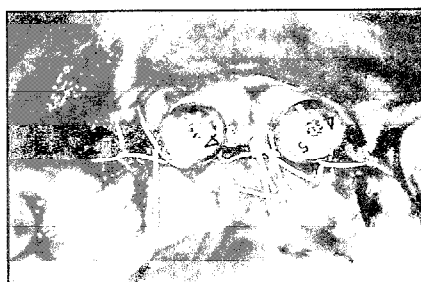


Fig 17 (right) Second surgical phase.

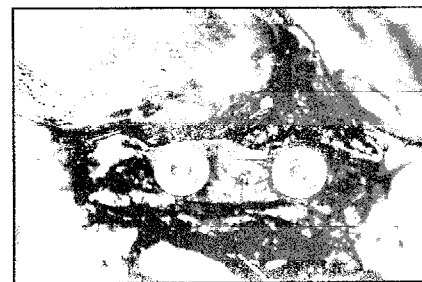

Fig 18 (left) View of the ridge, which has a thickness stabilized at 5 mm with good mineralization of the biograft material and PRP gel after only 3 months. The consistency is notable and the implants stable.

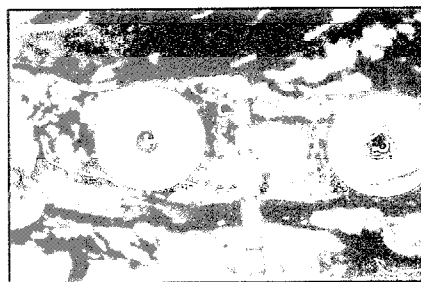
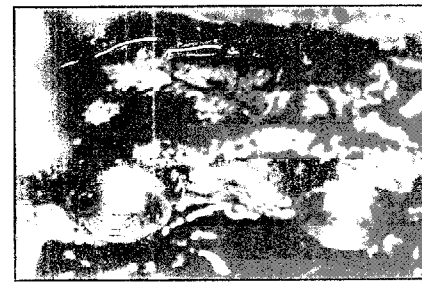

Fig 19 (right) Lateral view of the expanded ridge in which it is possible to see the integrity of the cortical wall. The photo shows heavy bleeding because of 2 factors: (1) the wound was opened after only 3 months; and (2) it was necessary to use a local anesthetic with only a small percentage of adrenaline because of the patient's hypertension.



encourage medullar bleeding (Fig 10). The bone defect obtained by the separation of the bone flaps was filled with Biogran (Orthovita), a bioactive glass synthetic bone graft material, and autogenous platelet-rich plasma (PRP) gel activated with Botropase (Botropase batroxobina, AIC Ravizza Farmaceutici) (Fig 11), which was then compacted and measured with a periodontal probe; the ridge then had a thickness of 5 mm (Fig 12). The ridge was covered with a PRP membrane (Fig 13) to protect and stabilize the graft. The flaps were then sutured on 2 sides with horizontal mattress stitches (Vicryl # 4/0, Ethicon/Johnson & Johnson) (Fig 14).

Three months after the ridge expansion, the second operation was performed to discover whether the implants had taken. At this time it was possible to see the implants under the mucosa in the absence of keratinized tissue (Fig 15). A palatal incision was made to design a flap of mixed thickness that opened toward the vestibule to guarantee about 3 mm of adherent gingiva on the vestibular side of the healing abutments (Fig 16). The ridge was well mineralized with a thickness of 5 mm (Figs 17 and 18), the implants were osseointegrated, and there was no sign of dehiscence or fenestration on the vestibular side (Fig 19).

## Results

During the second surgery, which was carried out after 12 weeks, the bone ridge appeared to be

stabilized at a thickness of 5 mm, an increase of 2 to 3 mm. The implants were stable and perfectly osseointegrated. The bone fracture rims of the releasing incisions appeared secure. The bioactive glass with PRP appeared to be mineralized. The vestibular and palatal cortical surfaces were eutrophic and did not show signs of dehiscence or fenestration.

## Discussion

This work presents a pilot study for the clinical use of piezoelectric surgery to expand thin edentulous ridges, even with a very mineralized residual bone crest. The possibility of expanding the ridge and positioning implants in single-stage surgery has been the object of continuous research in recent years. For example, the ridge expansion osteotomy of Summers<sup>14-16</sup> permits the positioning of standard implants (3.75 mm) in ridges of about 4 mm in thickness. This technique provides for the expansion of a single implant site, making use of the characteristics of bone elasticity: the bone gradually cedes to pressure exercised from inside by the positioning of osteotomes of increasing diameter until it is able to receive an implant that stabilizes the new thickness obtained from the dislocation of the bone tissue in the vestibular and palatal directions.

The osteotomy method is very effective in bone of quality 3 to 4 because it offers better expansion and primary stability. In the case of more mineralized bone (quality 1 to 2), this

method is limited by the physical nature of the material, which lacks the elasticity that can be overcome by the mechanical pressure of the osteotomes; this necessitates the use of burs and osteotomes that mostly leads to fractures that are responsible for notable dehiscence and/or fenestration and loss of the primary stability of the implants. Instead, in these situations it is possible to use the manually fractured bone flap technique, but only with a ridge of at least 3 to 4 mm in thickness on the cortical side, and only if the ridge has development with an increase in volume in the apical direction.

When bone atrophy is more severe because the edentulism is long standing, and the residual ridge is less than 3 mm, the bone is often of a very mineralized quality characterized by 2 cortical bones separated by a thin cancellous layer. The rehabilitation of such advanced anatomic situations with implants has until now been treated in 2 surgical stages, in the first of which bone is grafted to increase the volume, with implant placement in the second.

The new piezoelectric ridge expansion technique as demonstrated in this case report permits implant therapy in anatomic situations previously impossible in a single-stage surgical operation. In fact, the use of variable-frequency piezoelectric energy scalpels separates the bone flaps without the risk of accidental fracture because of excessive trauma. The case in this report was characterized by a severe anatomic difficulty that required very careful surgical attention, but it is symbolic

of how piezoelectric surgery can be used to resolve not only simple cases but also the more complex.

## Conclusions

1. Simultaneous ridge expansion and placement of implants can be obtained in single-stage surgery in an edentulous ridge that is 2 to 3 mm in thickness for its entire vertical extension.
2. The bone flap technique has been used successfully in the case of bone of quality 1 to 2 thanks to variable-frequency piezoelectric energy scalpels.
3. Stimulation of the medulla was performed with piezoelectric tips at the interface of the defect created by the bone separation, where a PRP gel and Biogran were inserted.
4. The piezoelectric ridge expansion technique is a new and promising procedure for ridge expansion in all cases, particularly in advanced ones; in fact, the periimplant healing is very predictable because it takes place in a protected and well-vascularized environment.

The author recommends the following sources for a complete understanding of the principles discussed in this article: (1) Lynch SE, Genco RJ, Marx RE (eds). *Tissue Engineering: Applications in Maxillofacial Surgery and Periodontics* (Chicago: Quintessence, 1999); and (2) Buser D, Dahlin C, Schenk RK (eds). *Guided Bone Regeneration in*

*Implant Dentistry* (Chicago: Quintessence, 1994).

## References

1. Albrektsson T, Zarb GA, Worthington P, Eriksson AR. The long-term efficacy of currently used dental implants. A review and proposed criteria of success. *Int J Oral Maxillofac Implants* 1986;1:11-25.
2. Adell R, Lekholm U, Grondahl K, Branemark P-I, Lindström J, Jacobsson M. Reconstruction of severely resorbed edentulous maxillae using osseointegrated fixtures in immediate autogenous bone grafts. *Int J Oral Maxillofac Implants* 1990;5:233-246.
3. Nevins M, Langer B. The successful application of osseointegrated implants to the posterior jaw: A long-term retrospective study. *Int J Oral Maxillofac Implants* 1993;8:428-432.
4. Cawood JI, Howell RA. A classification of the edentulous jaws. *Int J Oral Maxillofac Implants* 1988;17:232-236.
5. Dahlin C, Sennerby L, Lekholm U, Linde A, Nyman S. Generation of new bone around titanium implants using a membrane technique: An experimental study in rabbits. *Int J Oral Maxillofac Implants* 1989;4:19-25.
6. Dahlin C, Gottlow J, Linde A, Nyman S. Healing of maxillary and mandibular bone defects using a membrane technique. An experimental study in monkeys. *Scand J Plast Reconstr Hand Surg* 1990;24:13-19.
7. Dahlin C, Lekholm U, Becker W, Becker BE, Higuchi K, Callens A, van Steenberghe D. Treatment of fenestration and dehiscence bone defects around oral implants using the guided tissue regeneration technique: A prospective multicenter study. *Int J Oral Maxillofac Implants* 1995;10:312-318.
8. Mellonig JT, Nevins M. Guided bone regeneration of bone defects associated with implants: An evidence-based outcome assessment. *Int J Periodontics Restorative Dent* 1995;15:168-185.
9. Nevins M, Mellonig JT. Enhancement of the damaged edentulous ridge to receive dental implants: A combination of allograft and the Gore-Tex membrane. *Int J Periodontics Restorative Dent* 1992;12:97-111.
10. Nevins M, Mellonig JT. The advantages of localized ridge augmentation prior to implant placement: A staged event. *Int J Periodontics Restorative Dent* 1994;14:97-111.
11. Buser D, Dula K, Belser U, Hirt HP, Berthold H. Localized ridge augmentation using guided bone regeneration. I. Surgical procedure in the maxilla. *Int J Periodontics Restorative Dent* 1993;13:29-45.
12. Hammerle CHF, Schmid J, Olah AJ, Long NP. A novel model system for the study of experimental guided bone formation in humans. *Clin Oral Implants Res* 1996;7:38-47.
13. von Arx T, Hardt N, Wallkmann B. The TIME technique: A new method for localized alveolar ridge augmentation prior to placement of dental implants. *Int J Oral Maxillofac Implants* 1996;11:387-394.
14. Summers RB. A new concept in maxillary implant surgery: The osteotome technique. *Compendium* 1994;15:152-158.
15. Summers RB. The osteotome technique: Part 2—The ridge expansion osteotomy (REO) procedure. *Compendium* 1994;15:422-426.
16. Summers RB. The osteotome technique: Part 3—Less invasive methods of elevating the sinus floor. *Compendium* 1994;15:698-704.
17. Scipioni A, Bruschi GB, Calesini G. The edentulous ridge expansion technique: A five-year study. *Int J Periodontics Restorative Dent* 1994;14:451-459.